

Stroke

American Stroke
AssociationSM

A Division of American
Heart Association



JOURNAL OF THE AMERICAN HEART ASSOCIATION

Cerebral vasculitis associated with cocaine abuse
RK Fredericks, DS Lefkowitz, VR Challa and BT Troost

Stroke 1991, 22:1437-1439

doi: 10.1161/01.STR.22.11.1437

Stroke is published by the American Heart Association, 7272 Greenville Avenue, Dallas, TX 72514
Copyright © 1991 American Heart Association. All rights reserved. Print ISSN: 0039-2499. Online ISSN:
1524-4628

The online version of this article, along with updated information and services, is
located on the World Wide Web at:

<http://stroke.ahajournals.org/content/22/11/1437>

Subscriptions: Information about subscribing to *Stroke* is online at
<http://stroke.ahajournals.org/subscriptions/>

Permissions: Permissions & Rights Desk, Lippincott Williams & Wilkins, a division of Wolters
Kluwer Health, 351 West Camden Street, Baltimore, MD 21202-2436. Phone: 410-528-4050. Fax:
410-528-8550. E-mail:
journalpermissions@lww.com

Reprints: Information about reprints can be found online at
<http://www.lww.com/reprints>

Case Reports

Cerebral Vasculitis Associated With Cocaine Abuse

Ruth K. Fredericks, MD; David S. Lefkowitz, MD;
Venkata R. Challa, MD; and B. Todd Troost, MD

Background: Earlier reports of cocaine-associated cerebral vasculitis have been based primarily on angiographic findings without pathological verification.

Case Description: We present a case of acute encephalopathy following intravenous and intranasal administration of cocaine. Brain biopsy revealed vascular changes involving primarily small arteries. Findings included lymphocytic infiltration, endothelial thickening, and deposition of proteinaceous amorphous material within and around vessel walls.

Conclusions: These abnormalities are consistent with pathological features of arteritis previously reported in association with amphetamine and multiple-drug abuse. Vasospasm-induced changes are an alternative explanation for the vascular picture seen in this case. The patient made modest improvement with high-dose intravenous steroids. (*Stroke* 1991;22:1437-1439)

Cerebral vasculitis has been attributed to cocaine abuse in two reports on the basis of angiography^{1,2} and on pathological grounds in two other patients.³ Cerebral vasculitis has been demonstrated pathologically in two additional cases with multiple drug abuse, including cocaine and methamphetamines.^{4,5} We present a case of histologically verified cerebral vasculitis temporally related to cocaine use and not confounded by concurrent abuse of recreational drugs other than ethanol.

Case Report

A 24-year-old right-handed female presented to an outlying emergency room for evaluation of inappropriate behavior. She had been found attempting to light a fire on a kitchen floor shortly after using intravenous and intranasal cocaine. She was currently using 4–6 ounces of ethanol daily and had used marijuana in the remote past. She was discharged from the emergency department with a diagnosis of panic disorder. She continued to exhibit bizarre behavior and was committed to a psychiatric facility, where she was noted to be dysphasic, responding inappropriately, ataxic, and hypertonic in all extremities. Three days after the onset of symptoms, she was transferred to our institution for further evaluation. She had no history of a recent

intercurrent illness, hypertension, diabetes, or previous vascular disease.

On physical examination, her blood pressure was 110/80 mm Hg and pulse was 72 and regular. She was arousable, but her speech was slurred and her answers inappropriate. She was globally confused and combative. Right–left disassociation was present. Cranial nerves were intact. Motor exam was difficult to assess, but there were no asymmetries of strength, and tone was increased throughout. Appendicular ataxia was noted. Deep tendon reflexes were 3+/4 in the arms and 4+/4 in the legs with ankle and patellar clonus bilaterally. There were bilateral extensor plantar responses. Gait could not be evaluated.

Normal laboratory tests included complete blood cell count; prothrombin time; partial thromboplastin time; electrolytes; erythrocyte sedimentation rate; human immunodeficiency virus titers; toxoplasmosis, other viruses, rubella, cytomegalovirus, herpes (TORCH) titers; antinuclear antibody; latex and sheep cell agglutination tests for rheumatoid factor; immune complexes; hepatitis screen; and blood cultures. Urine drug screen performed at the psychiatric facility the day after onset of symptoms was positive only for cocaine. Lumbar puncture revealed clear, colorless fluid under normal pressure with 10 mononuclear cells/mm³, normal glucose, and a protein of 185 mg/dl. Cerebrospinal fluid cultures and gram stain were negative. Chest roentgenogram and echocardiogram were normal. Electroencephalography revealed diffuse delta activity. Computed cranial tomography was normal. T₂-weighted magnetic resonance imaging revealed multiple foci of increased signal in the deep white matter and basal ganglia

From the Departments of Neurology (R.K.F., D.S.L., B.T.T.) and Pathology (V.R.C.), Bowman Gray School of Medicine of Wake Forest University, Winston-Salem, N.C.

Address for reprints: David Lefkowitz, MD, Department of Neurology, Bowman Gray School of Medicine of Wake Forest University, 300 South Hawthorne Road, Winston-Salem, NC 27103.

Received February 19, 1990; accepted June 5, 1991.

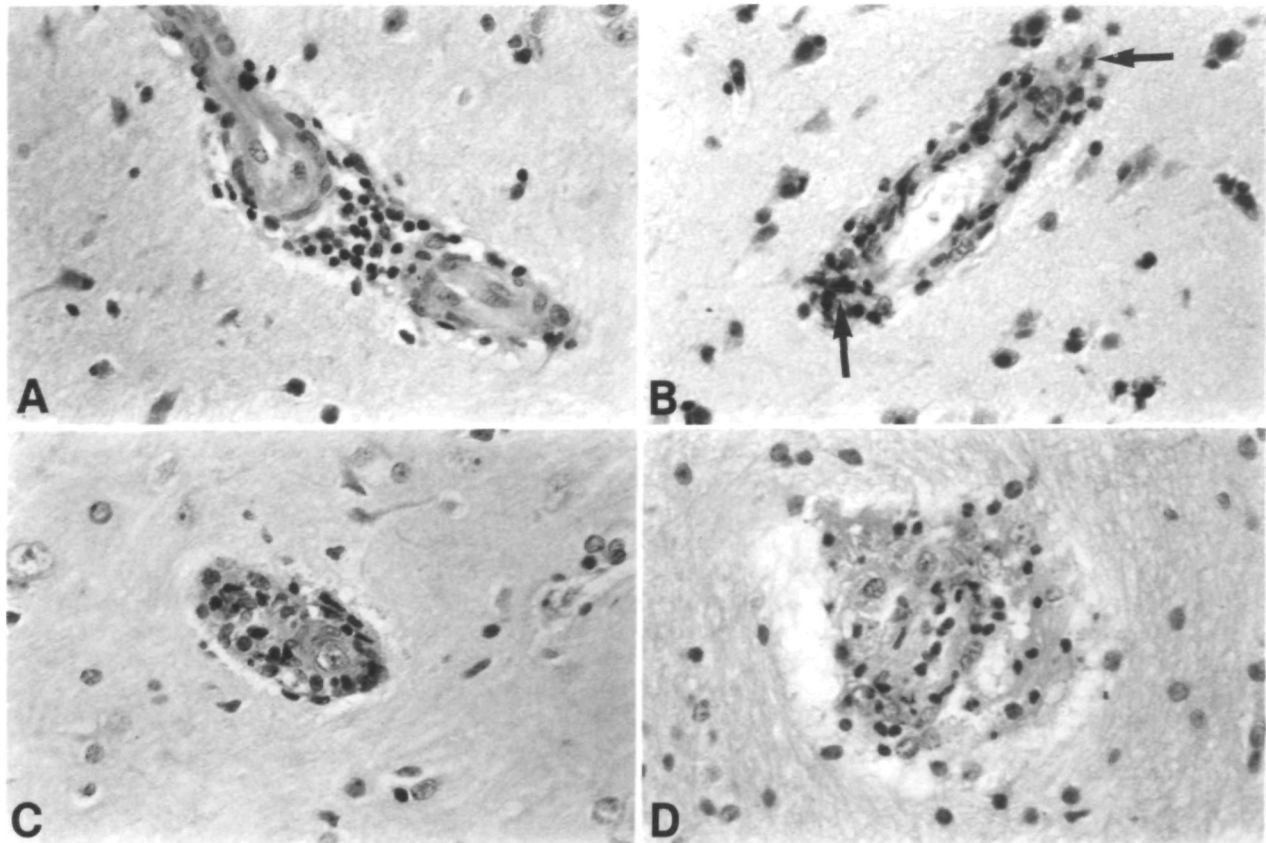


FIGURE 1. Brain biopsy showing four small arterioles in different stages of histological change. In panel A, there are collections of lymphocytes around the vessel. In panel B, lymphocytes are in and around a vessel wall. Arrows indicate cells positive for leukocyte-common antigen (LCA). Panel C shows a swollen endothelial cell and surrounding white cells, but vessel shows surrounding proteinaceous exudate and white blood cells in lumen and wall. In panel D, a smudged small vessel shows surrounding proteinaceous exudate and white blood cells in lumen and outside wall. Panels A, C, and D are stained with hematoxylin and eosin and panel B with immunocytochemical stain for LCA. Magnification, $\times 200$.

bilaterally. Gadolinium–diethylenetriamine pentaacetic acid infusion disclosed small punctate enhancing lesions in the deep white matter of both cerebral and cerebellar hemispheres. Cerebral angiography performed 4 days after the ictus was normal.

A right frontal brain biopsy was performed 10 days after admission in an area of white matter change on magnetic resonance imaging. Cortical neurons and glia were normal. Lymphocytes were noted in perivascular collections and within the walls of several small arteries (Figure 1, panels A and D). Some of the lymphocytes within the vessel wall stained positively for leukocyte-common antigen (Figure 1B). There were foci of interstitial edema in the immediate vicinity of small arteries and, in other areas, the perivascular spaces were enlarged and contained proteinaceous material. There was endothelial swelling of some small arterioles (Figure 1, panels C and D). These findings were not located near any zone of infarction. Meninges were noted to contain sparse lymphocytes. No foreign material was noted with polarized light. Special stains for microorganisms, amyloid, and fibrin were negative. There was no

necrosis, leukocytoclasia, giant cells, granulomas, or positive immunoglobulin G immunofluorescence.

After a 5-day course of high-dose intravenous steroids, the patient was more coherent and was oriented to person, place, and situation, but not to time. Neuropsychological evaluation before and after steroid therapy documented a marginal, but measurable, improvement in alertness and clinical behavior with evidence of qualitative improvement in memory performance. The patient has been followed on an outpatient basis at 3-month intervals. Her ataxia has slowly improved and now, 37 months after the insult, she walks unassisted.

Discussion

Neurological complications of cocaine include cerebral and spinal cord infarction, transient cerebral ischemia, ischemic optic neuropathy, partial and generalized seizures, and intracerebral and subarachnoid hemorrhage.^{1,6} Approximately 80% of cerebrovascular complications are hemorrhagic, and the majority of these are associated with underlying vascular lesions, such as aneurysms and arteriovenous malformations.^{1,7} Transient hypertension, vasospasm, migraine, and vas-

culitis have also been suggested as mechanisms of cocaine-induced cerebrovascular disease.^{1,8}

Drug-associated cerebral vasculitis has been best documented with amphetamine abuse. A multiorgan system necrotizing vasculitis resembling polyarteritis nodosa has been reported in patients using amphetamine alone or with other drugs.⁹ Intravenous methamphetamine has been shown to produce transient decreased vessel diameter in rhesus monkeys within 1 hour of administration.¹⁰ Arteriographic changes consistent with vasculitis have been reported with other recreational drugs, including phenylpropanolamine,^{11–13} ephedrine,¹⁴ pseudoephedrine,¹⁵ and heroin.¹⁶

Previous reports of vasculitis associated with drug abuse have been flawed by a lack of pathological verification and the frequent history of multiple-drug use. Two previous cases of cerebral vasculitis ascribed to cocaine abuse, one with intracerebral hemorrhage¹ and the other with ischemic infarction,² were diagnosed exclusively on the basis of the non-specific angiographic finding of segmental constriction or beading. There are two reports of pathologically proven cerebral vasculitis in patients with concurrent abuse of intravenous cocaine, heroin, and amphetamines, in whom vasculitis was attributed to the amphetamines.^{4,5} Only two published cases with biopsies verified that small-vessel vasculitis existed in patients with cocaine abuse who had no history of concomitant drug use.³

Our patient presented with multifocal ischemia shortly after using intravenous and inhaled cocaine. She had no history of concurrent use of heroin or amphetamines, nor were these agents present on a drug screen performed within 24 hours of the event. The pathological changes in the small arteries and arterioles in her brain biopsy are similar to those previously reported by Citron et al⁹ and Kessler et al⁴ in patients with multidrug-induced vasculitis, by Rumbaugh et al¹⁰ in experimental animals given methamphetamine, and by Krendel et al³ in patients with cocaine abuse. The sparing of capillaries and veins, amorphous eosinophilic deposits, and intimal thickening seen in our patient have also been described previously in patients with drug abuse.^{4,5}

We speculate that the vascular changes described in the brain biopsy may be secondary to hypersensitivity angiitis or angiospasm. Despite the absence of fibrinoid necrosis, leukocytoclastic infiltration, and immunofluorescent material, the morphological changes may reflect the stage of the disease during which the biopsy was obtained. Hypersensitivity angiitis has been noted in endomyocardial biopsies from cocaine abusers.¹⁷ It is also conceivable that these findings represent a response to vascular spasm. The literature on cocaine-induced myocardial ischemia and infarction emphasizes the pharmacological effects of cocaine on coronary artery smooth muscle.^{18,19} Lange et al¹⁸ have demonstrated α -adrenergic-mediated coronary artery vasoconstriction in patients receiving pharmacological doses of intranasal cocaine. However, no such evidence

exists to support the occurrence of cerebrovascular spasm due to cocaine. Intraluminal thrombosis has been found in some cases with cocaine-related myocardial infarction.¹⁷ In vitro studies indicate that cocaine increases thromboxane synthesis and platelet reactivity to arachidonic acid.¹ The presence of lesions at various stages makes direct toxicity a less plausible explanation for these findings.

In conclusion, this case supports the existence of a nonnecrotizing, nonleukocytoclastic small-vessel arteritis associated with lone cocaine use. One should consider a diagnosis of cerebral vasculitis in the cocaine abuser with signs of focal or diffuse central nervous system dysfunction. The incidence and etiology of this disorder remain speculative. The role of steroid therapy warrants further investigation.

References

1. Klonoff DC, Andrews BT, Obana WG: Stroke associated with cocaine use. *Arch Neurol* 1989;46:989–993
2. Kaye BR, Fainstat M: Cerebral vasculitis associated with cocaine abuse. *JAMA* 1987;258:2104–2106
3. Krendel DA, Ditter SM, Frankel MR, Ross WK: Biopsy-proven cerebral vasculitis associated with cocaine abuse. *Neurology* 1990;40:1092–1094
4. Kessler JT, Jortner BS, Adapon BD: Cerebral vasculitis in a drug abuser. *J Clin Psychol* 1978;39:559–564
5. Bostwick DG: Amphetamine induced cerebral vasculitis. *Hum Pathol* 1981;12:1031–1033
6. Mody CK, Miller BL, McIntyre HB, Cobb SK, Goldberg MA: Neurologic complications of cocaine abuse. *Neurology* 1988;38:1189–1193
7. Wojak JC, Flamm ES: Intracranial hemorrhage and cocaine use. *Stroke* 1987;18:712–715
8. Levine SR, Washington JM, Jefferson MF, Kieran SN, Moen M, Feit H, Welch KMA: "Crack" cocaine-associated stroke. *Neurology* 1987;37:1849–1853
9. Citron BP, Halpern M, McCarron M, Lundberg GD, McCormick R, Pincus IJ, Tatter D, Haverback BJ: Necrotizing angiitis associated with drug abuse. *N Engl J Med* 1970;283:1003–1011
10. Rumbaugh CL, Bergeron RT, Scanlan RL, Teal JS, Segall HD, Fang HCH, McCormick R: Cerebral vascular changes secondary to amphetamine abuse in the experimental animal. *Radiology* 1971;101:345–351
11. Stoessel AJ, Young GB, Feasby TE: Intracerebral hemorrhage and angiographic beading following ingestion of catecholaminergics. *Stroke* 1985;16:734–736
12. Fallis RJ, Fisher M: Cerebral vasculitis and hemorrhage associated with phenylpropanolamine. *Neurology* 1985;35:405–407
13. Kase CS, Foster TE, Reed JE, Spatz EL, Girgis GN: Intracerebral hemorrhage and phenylpropanolamine. *Neurology* 1987;37:399–404
14. Wooten MR, Khangure MS, Murphy MJ: Intracerebral hemorrhage and vasculitis related to ephedrine abuse. *Ann Neurol* 1983;13:337–340
15. Loizou LA, Hamilton JG, Tsementzis SA: Intracranial hemorrhage in association with pseudoephedrine overdose. *J Neurol Neurosurg Psychiatry* 1982;45:471–472
16. King J, Richards M, Tress B: Cerebral arteritis associated with heroin abuse. *Med J Aust* 1978;2:444–445
17. Levine SR, Welch KMA: Cocaine and stroke. *Stroke* 1988;19:779–783
18. Lange RA, Cigarroa RG, Yancy CW, Willard JE, Popma JJ, Sills MN, McBride W, Kim AS, Hillis LD: Cocaine-induced coronary artery vasoconstriction. *N Engl J Med* 1989;321:1557–1562
19. Isner JM, Chokshi SK: Cocaine and vasospasm. *N Engl J Med* 1989;321:1604–1606

KEY WORDS • cocaine • vasculitis